

# Ultrasound-guided-fine-needle Aspiration Drainage and Percutaneous Ethanol Injection for Benign Neck Cysts

CME  
Credits

Li-Jen Liao<sup>1,2,3</sup>, Chi-Te Wang<sup>1,3</sup>, Tsung-Wei Huang<sup>1,2</sup>, Po-Wen Cheng<sup>1</sup>, Wu-Chia Lo<sup>1\*</sup>

<sup>1</sup>Department of Otolaryngology Head and Neck Surgery, Far Eastern Memorial Hospital, New Taipei, Taiwan, <sup>2</sup>Department of Electrical Engineering, Yuan Ze University, Taoyuan, Taiwan, <sup>3</sup>Biomedical Engineering Office, Far Eastern Memorial Hospital, New Taipei, Taiwan

## Abstract

**Background:** Ultrasound-guided-fine-needle aspiration drainage (US-FNAD) and US-percutaneous ethanol injection (US-PEI) have been widely used in the management of benign neck cysts. However, the long-term results of US-FNAD and US-PEI are not well elucidated. **Methods:** We retrospectively collated patients under neck US examinations from March 2007 to December 2017 and investigated the recurrence after US-FNAD and US-PEI. Univariate and multivariate Cox regression analyses were used to assess significant risk factors for recurrence after US-FNAD. **Results:** A total of 1075 patients were recruited, and their age was  $50 \pm 15$  (mean  $\pm$  standard deviation) years. A total of 862 patients had thyroid cysts, 118 patients had thyroglossal duct cysts (TGDC), twenty patients had branchial cleft cysts, 64 patients had parotid sialocysts, and 11 patients had plunging ranulas. Majority of the patients (97%, 1037/1075) reported significant symptom improvement immediately. However, 38% of the patients had recurrence with a median 3-year follow-up period. In a multivariate Cox regression analysis with adjustment for age and gender, plunging ranula (hazard ratio [HR]: 2.44, 95% confidence interval [CI]: 1.19–4.99) and lateral dimension size  $\geq 0.8$  cm (HR: 1.32, 95% CI: 1.04–1.67) after US-FNAD were independent risk factors for recurrence. There were 15 male and 19 female patients who received US-PEI therapy after repeated US-FNAD, of whom 23 patients had thyroid cysts, 6 had plunging ranulas, 4 had TGDC, and one had a branchial cleft cyst. The overall success rate was 94% (32/34), with a median follow-up period of 1.6 years. Two recurrent symptomatic patients had plunging ranulas. Some patients stated mild pain (21%, 7/34) and swelling sensation (26%, 9/34) after the injection. No major complications, such as vocal fold paresis or airway compression, were found. **Conclusion:** US-FNAD is an effective tool in the management of benign neck cysts with a 38% recurrence rate. Plunging ranulas have the highest rate of recurrence after FNAD. US-PEI is effective for most recurrent neck cysts after repeated US-FNAD.

**Keywords:** Fine-needle aspiration, percutaneous ethanol injection, ultrasound

## INTRODUCTION

Cystic masses of the neck are frequently encountered clinically. Although clinical history and examination may suggest a diagnosis, with imaging, we can further assess the anatomical extent of the lesion to confirm the clinical diagnosis before treatment. Cystic masses of the neck include a wide range of congenital and acquired lesions. Common benign neck cystic masses include thyroid cysts, thyroglossal duct cysts (TGDC), branchial cleft cysts, parotid sialocysts, ranulas, and lymphangiomas.<sup>[1]</sup>

Thyroid cysts are those thyroid lesions having a delimiting wall with a dominant fluid content. Parotid cysts are also called parotid sialoceles, which are parotid lesions with fluid

content in the parotid glands. TGDCs are along the course of the embryonic thyroglossal duct and are cystic lesions within the midline neck between the tongue base and thyroid gland. Branchial cleft cysts are congenital epithelial cysts located in the lateral neck. A ranula is a pseudocyst or mucocele caused by saliva leakage from the sublingual or minor salivary gland, and plunging ranula means that the pseudocyst extends through the mylohyoid muscle to the upper neck region.

High-resolution ultrasound (US) is a convenient tool for initial evaluation. An increasing number of head-and-neck surgeons

**Address for correspondence:** Dr. Wu-Chia Lo,

No. 21, Sec. 2, Nanya S. Rd., Banqiao Dist., New Taipei City 220, Taiwan.

E-mail: lowuchia@gmail.com

Received: 22-11-2019 Revised: 10-01-2020 Accepted: 12-02-2020 Available Online: 24-08-2020

### Access this article online

#### Quick Response Code:



**Website:**  
[www.jmuonline.org](http://www.jmuonline.org)

**DOI:**  
10.4103/JMU.JMU\_111\_19

This is an open access journal, and articles are distributed under the terms of the Creative Commons Attribution-NonCommercial-ShareAlike 4.0 License, which allows others to remix, tweak, and build upon the work non-commercially, as long as appropriate credit is given and the new creations are licensed under the identical terms.

**For reprints contact:** WKHLRPMedknow\_reprints@wolterskluwer.com

**How to cite this article:** Liao LJ, Wang CT, Huang TW, Cheng PW, Lo WC. Ultrasound-guided-fine-needle-aspiration drainage and percutaneous ethanol injection for benign neck cysts. J Med Ultrasound 2020;28:225-9.

use US to check neck lumps. With the assistance of US, fine-needle aspiration (FNA) or core needle biopsy can harvest specimens for further cytological or pathological examination. Symptomatic benign cysts can be managed with US-FNA drainage (US-FNAD), although some of the cysts will recur.<sup>[2]</sup>

Management of benign neck cysts has moved toward a patient-tailored approach.<sup>[3]</sup> Medication plays a minor role in the management of benign neck cysts if no infection occurs. Surgery is the mainstay of treatment for benign neck cysts. Recently, office-based minimally invasive treatment (MIT) has become an alternative for the management of benign cysts.<sup>[3,4]</sup> The choices of MIT include percutaneous ethanol injection (PEI) and thermal ablation, such as LASER, radiofrequency,<sup>[5]</sup> and high-intensity focus US therapy.<sup>[2,6,7]</sup> In ATA guidelines, relapsing thyroid cysts are indicated for PEI treatment.<sup>[8]</sup>

US-PEI has been reported to successfully treat thyroid cysts,<sup>[3,9-11]</sup> TGDC,<sup>[12-14]</sup> branchial cleft cysts,<sup>[15]</sup> lymphangiomas,<sup>[16]</sup> and ranulas.<sup>[17]</sup> Both US-FNAD and US-PEI have been widely used in the management of benign neck cysts. However, the long-term results of US-FNAD and US-PEI have not been well elucidated. The present study aimed to clarify the long-term effects of US-FNAD and PEI in the management of benign neck cysts.

## MATERIALS AND METHODS

This study was approved by the institutional research board (107102-E). We retrospectively collated patients who underwent head-and-neck US examinations from March 2007 to December 2017, and only benign neck cysts were taken for further review and analysis. The benign neck cystic masses included predominant thyroid cysts (>50% of fluid component), TGDC, branchial cleft cysts, parotid sialocysts, and plunging ranulas.

### Ultrasound examination and ultrasound-guided-fine-needle aspiration drainage

All patients received US examinations due to palpable or symptomatic neck lumps in an outpatient clinical setting. The patients underwent both US and US-FNA cytology examinations. The detailed procedure of US examination and US-FNA was well described in a previous publication.<sup>[18]</sup> We aspirated and drained the internal content of the cyst as much as possible (at least >50%) with an 18G needle. We recorded the diameters pre- and post-aspiration. When the cytology revealed benign results, the patients could be further enrolled for analysis. The medical records were reviewed to determine the location and size of the lesions before the aspiration, the results of cytological examination, and whether those cysts were recurrent.

### Ultrasound-guided-percutaneous ethanol injection procedure

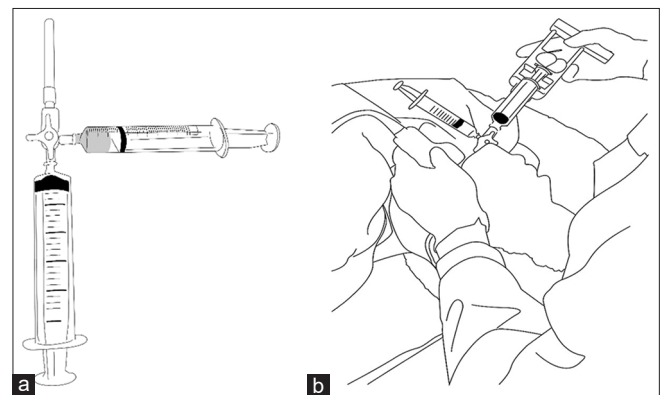
Patients who underwent US examinations and US-PEI were also included in the retrospective analysis. If these patients

still had symptoms after more than two times of aspiration drainage and cytology shown no evidence of malignancy, then we would suggest the alternative choice of US-PEI to patients. Before PEI, local anesthetic of 1 ml 2% xylocaine was injected subcutaneously. Then, we took an 18G needle with a three-head connection device connected to a 20-ml syringe and 2 ml of 95% alcohol in another syringe [Figure 1a] to perform the procedure. Under the guidance of US, cyst fluid was withdrawn by the 18G needle as completely as possible, and the needle was kept in the cyst visually under the US screen. Then, through the three-way joint device, 2 ml of alcohol was injected into the target cyst after rotating the direction knob [Figure 1b]. After the procedure, moderate pressure was applied to the injection site and observed for 15 min. The treatment response was determined 1 week after the treatment. If the response was not good and the patient persisted with the symptomatic lump, the patient was scheduled to receive repeated US-PEI. Therefore, several rounds of US-PEI might have been performed.

In the follow-up clinic, each patient who had been injected with alcohol was examined and inquired to see whether the patient had relapse or had other side effects (hoarseness, pain, or swelling). The follow-up time was determined by the duration between US-FNAD or US-PEI and the last clinical follow-up.

## Statistical analysis

Categorical data were expressed in numbers and percentages, and continuous data were expressed as mean  $\pm$  standard deviation (SD) or median (interquartile range [IQR]), when appropriate. Statistical analysis was used to investigate the recurrence of cysts after US-FNAD. A K-M plot with a log-rank test was used to compare the recurrence rates of different cysts. Univariate and multivariate Cox regression analyses were used to assess significant risk factors for recurrence after US-FNAD.  $P < 0.05$  was considered statistically significant for all analyses. Statistical analyses were performed with STATA 12 (Stata Corp LP, College Station, TX, USA).



**Figure 1:** The preparation of ultrasound-percutaneous ethanol injection. The 18G needle and 20-mL syringe were filled with 95% alcohol (a). Under the real-time guidance of ultrasound, the fluid of the cyst was drainage out with a 3-way connector, and 2 ml of 95% alcohol was pushed into the cystic cavity (b)

## RESULTS

A total of 1075 patients, including 380 males and 695 females, were recruited. Their age was  $50 \pm 15$  (mean  $\pm$  SD) years. The detailed patient characteristics are summarized in Table 1. The median follow-up period was 3 years (IQR: 1.9 years). A total of 862 patients had thyroid cysts (predominant cysts >50%), 118 patients had TGDC, 20 patients had branchial cleft cysts, 64 patients had parotid cysts, and 11 patients had plunging ranulas. We found that US-FNAD was effective in the management of benign neck cysts immediately. Majority of the patients (97%, 1037/1075) reported significant shrinkage or improvement in swelling symptoms. However, 38% (412/1075) of the patients had recurrence after one US-FNAD. The recurrence rates were 39% (333/862), 34% (40/118), 40% (8/20), 36% (23/64), and 73% (8/11) for thyroid cysts, TGDC, branchial cleft cysts, parotid cysts, and plunging ranulas, respectively. The median duration from

the first US-FNAD to the recurrence was 177 (IQR 267), 167 (462), 205 (679), 294 (656), and 78 (293) days for thyroid cysts, TGDC, branchial cleft cysts, parotid cysts, and plunging ranulas, respectively.

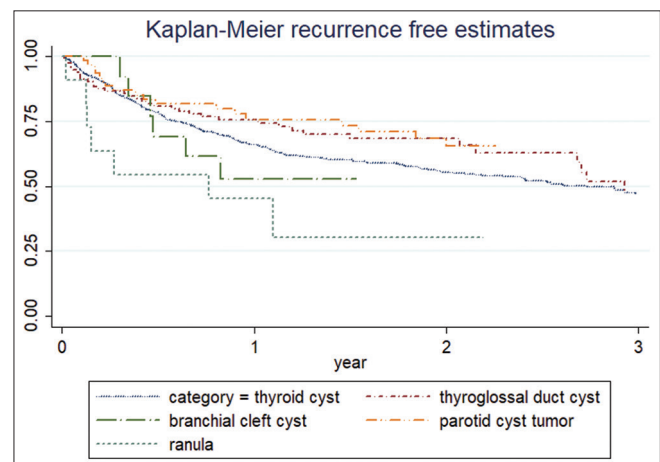
In the K-M plot, we found that plunging ranulas had a higher recurrence rate [Figure 2]. We used Cox regression analyses to compare the risk of recurrence after US-FNAD [Table 2]. On univariate analysis, compared to the thyroid cysts, plunging ranulas had a higher recurrence risk (hazard ratio [HR]: 2.43, 95% confidence interval [CI]: 1.21–4.91). For the cystic size comparisons, the anteroposterior (AP) size  $\geq 1.2$  cm and lateral size  $\geq 2$  cm before US-FNAD and the AP size  $\geq 0.5$  cm and lateral size  $\geq 0.8$  cm after US-FNAD had significantly higher recurrence risks. On multivariate Cox regression analysis with adjustments for age and gender, plunging ranula (HR: 2.44, 95% CI: 1.19–4.99) and lateral dimension size  $\geq 0.8$  cm (HR: 1.32, 95% CI: 1.04–1.67) after US-FNAD were found to be independent risk factors for recurrence.

There were 34 patients who underwent US-PEI therapy. The clinical and demographic data are summarized in Table 3. There were 15 male and 19 female patients who received the therapy. All patients received more than two rounds of US-FNAD and suffered from symptomatic recurrence. Of these, 23 patients had thyroid cysts, 6 had plunging ranulas, 4 had TGDC, and one had a branchial cleft cyst. The AP and lateral dimensions for these cysts were  $2.17 \pm 0.66$  and  $3.28 \pm 1.12$  cm, respectively. The median follow-up time was 1.6 years (IQR: 1.3 years). The average number of injections for thyroid cysts, TGDC, branchial cleft cysts, parotid cysts, and ranulas was 1.8, 1.25, 1, and 2 injections, respectively. The overall success rate was 94% (32/34). Two patients who had persistent symptoms had plunging ranulas. Some patients stated mild pain (21%, 7/34) and swelling sensation (26%, 9/34) after the injection. No major complications, such as vocal fold paresis or airway compression, were found.

**Table 1: Patients' characteristics (n=1075)**

Item	n (%), mean $\pm$ SD or median $\pm$ IQR
Gender	
Male	380 (35)
Female	695 (65)
Age (years)	50 $\pm$ 15
Locations	
Thyroid cyst	862 (80)
Thyroglossal duct cyst	118 (11)
Branchial cleft cyst	20 (2)
Parotid cyst tumor	64 (6)
Ranula	11 (1)
Size before the 1 <sup>st</sup> aspiration	
AP L dimensions (cm)	
Thyroid cyst	1.7 $\pm$ 0.7, 2.4 $\pm$ 1.0
Thyroglossal duct cyst	1.4 $\pm$ 0.7, 2.2 $\pm$ 0.9
Branchial cleft cyst	2.2 $\pm$ 1.0, 3.3 $\pm$ 1.4
Parotid cyst tumor	1.7 $\pm$ 0.6, 2.4 $\pm$ 1.0
Plunging ranula	2.2 $\pm$ 0.9, 3.3 $\pm$ 1.4
Recurrent rate and time, median (IQR, days)	
Overall: 412/1075 (38%)	177 (294)
Thyroid cyst (333/862, 39%)	177 (267)
Thyroglossal duct cyst (40/118, 34%)	167 (462)
Branchial cleft cyst (8/20, 40%)	205 (679)
Parotid sialocysts (23/64, 36%)	294 (656)
Plunging ranula (8/11, 73%)	78 (293)
Surgery (n=99)	
Thyroid cyst	63 (64)
Thyroglossal duct cyst	14 (14)
Branchial cleft cyst	6 (6)
Parotid cyst tumor	15 (15)
Ranula	1 (1)
Pathology	
Benignity	99 (100)
Malignancy	0

SD: Standard deviation, IQR: Interquartile range, L: Lateral, AP: Anteroposterior



**Figure 2:** Comparison of the recurrence rate of ultrasound-guided-fine-needle aspiration drainage for different types of benign neck cysts in the K-M plot. The recurrence risk was higher for plunging ranulas ( $P < 0.05$  with the log-rank test)

**Table 2: Cox regression analysis of the risk for recurrence after ultrasound-guided-fine-needle aspiration drainage**

	Univariate			Multivariate		
	HR	95% CI	P	HR	95% CI	P
Gender (male/female)	1.11	0.91-1.36	0.29	1.05	0.85-1.29	0.64
Age ( $\geq 50$ / $<50$ )	1.10	0.91-1.34	0.32	1.08	0.88-1.33	0.44
Diagnosis						
Thyroid cyst	1			1		
Parotid cyst	0.71	0.46-1.08	0.11	0.15	0.45-1.06	0.09
Thyroglossal duct cyst	0.85	0.61-1.18	0.32	0.92	0.65-1.29	0.63
Branchial cleft cyst	1.48	0.73-2.98	0.28	1.28	0.63-2.60	0.50
Ranula	2.43	1.21-4.91	0.01*	2.44	1.19-4.99	0.02*
Size (cm)						
Pre-FNA AP ( $\geq 1.2$ / $<1.2$ )	1.45	1.15-1.83	0.002*	1.13	0.85-1.51	0.39
Pre-FNA L ( $\geq 2.0$ / $<2.0$ )	1.46	1.20-1.78	$<0.001$ *	1.19	0.92-1.53	0.18
Post-FNA AP ( $\geq 0.5$ / $<0.5$ )	1.45	1.19-1.77	$<0.001$ *	1.22	0.97-1.53	0.10
Post-FNA L ( $\geq 0.8$ / $<0.8$ )	1.58	1.30-1.93	$<0.001$ *	1.32	1.04-1.67	0.02*

\* $P < 0.05$ . L: Lateral, AP: Anteroposterior, FNA: Fine-needle aspiration, HR: Hazard ratio, CI: Confidence interval**Table 3: Patient characteristics and results of percutaneous ethanol injection**

Item	Number (%), Range or Mean $\pm$ SD
Gender, n (%)	
Male	15 (44)
Female	19 (56)
Age (years), mean $\pm$ SD	20-74, 43.7 $\pm$ 15.8
Thyroid cyst, n (%)	23 (67)
Plunging ranula, n (%)	6 (18)
Thyroglossal duct cyst, n (%)	4 (12)
Branchial cleft cyst, n (%)	1 (3)
Size (cm), mean $\pm$ SD	
AP-dimension	0.99-4.14, 2.17 $\pm$ 0.66
L-dimension	1.42-6.08, 3.28 $\pm$ 1.12
Complications, n (%)	
Mild pain	7 (21)
Swelling sensation	9 (26)
Follow-up (years), median (IQR)	1.6 (1.3)
Final results, n (%)	
Recurrence	2 (6)
No recurrence	32 (94)

SD: Standard deviation, IQR: Interquartile range, L: Lateral, AP: Anteroposterior

## DISCUSSION

Our study presents a large cohort of benign neck cysts that received US-FNAD and long-term follow-up after US-PEI. For benign neck cysts, US-FNAD can decrease the size and improve the symptoms. However, some patients suffer from recurrence and require repeated US-FNAD. We found that 38% of the patients had recurrence. The recurrence risk was higher for plunging ranulas and larger cysts before and after US-FNAD. US-PEI offered a high success rate for recurrent neck cysts after repeated US-FNAD during long follow-up times.

US-PEI is one kind of US-guided minimally invasive treatment procedure. The chemical effects of ethanol injection cause

cellular dehydration, protein denaturation, hemorrhage infraction and result in fibrosis, and finally regression and shrinkage of the cysts.

Previous studies have various indications and techniques for PEI;<sup>[7]</sup> some studies do irrigation of the cyst wall with normal saline to avoid debris coating in the inner wall of the cyst.<sup>[13]</sup> The concentration and volume of ethanol are also different among studies. Some studies keep the ethanol in the cysts, whereas others drain out the ethanol after the procedure.<sup>[7]</sup> Up to date, there are no rigid consensus for the indications and procedure of US-PEI. For the outcome of PEI, the size and content of the fluid might have impact on the recurrence rate. The larger the cyst volume, the higher the recurrence rate and greater the times of PEI.<sup>[10]</sup> Some colloid cysts or sticky old hematoma might not be completely aspirated out and also result in higher recurrent rate. Plunging ranula is a pseudocyst or mucocoele caused by saliva leakage from the sublingual or minor salivary gland through the mylohyoid muscle to the upper neck region. In our opinion, the secretion of saliva might result in the high recurrence rate of plunging ranula after US-FNAD and US-PEI.

In our study, US-PEI was effective in the management of recurrent benign neck cysts. We noted that plunging ranulas had a higher recurrence rate for both US-FNAD and US-PEI. The complications of US-FNAD and US-PEI were transient mild pain and swelling. The use of PEI in the treatment of solid thyroid nodules remains controversial. Some reported that using PEI in the management of solid thyroid nodules could decrease the size.<sup>[19,20]</sup> However, severe complications with toxic necrosis of the larynx and adjacent skin have been reported.<sup>[21]</sup> Therefore, we did not use PEI to treat solid thyroid adenoma in our institute.

There are still some limitations in this study. First, the number of patients in the PEI group is limited. More cases are necessary to clarify the potential complications. Second, we used only 2 ml of alcohol for the injections. The amount is less than



that reported, which is up to 50%–80% of the amount of cystic fluid in previous literature. Fewer alcohol injections may decrease the effect of PEI. Third, we did not arrange US follow-up regularly, and the recurrence was according to clinical examination and patients' subjective perceptions.

## CONCLUSION

In summary, US-FNAD is an effective management of benign neck cysts with a 38% recurrent rate, and plunging ranulas have a greater chance of recurrence. US-PEI is effective for most recurrent neck cysts after repeated US-FNAD.

## Financial support and sponsorship

This work was supported by a grant from the Far Eastern Memorial Hospital Research Program (FEMH-2019-C-016). This funding source had no role in the design of this study and will not have any role during its execution, analyses, interpretation of the data, or decision to submit the results.

## Conflicts of interest

There are no conflicts of interest.

## REFERENCES

- Mittal MK, Malik A, Sureka B, Thukral BB. Cystic masses of neck: A pictorial review. *Indian J Radiol Imaging* 2012;22:334-43.
- Papini E, Pacella CM, Solbiati LA, Achille G, Barbaro D, Bernardi S, *et al.* Minimally-invasive treatments for benign thyroid nodules: A Delphi-based consensus statement from the Italian minimally-invasive treatments of the thyroid (MITT) group. *Int J Hyperthermia* 2019;36:376-82.
- Papini E, Pacella CM, Misichi I, Guglielmi R, Bizzarri G, Døssing H, *et al.* The advent of ultrasound-guided ablation techniques in nodular thyroid disease: Towards a patient-tailored approach. *Best Pract Res Clin Endocrinol Metab* 2014;28:601-18.
- Brzac HT. Ultrasonography-guided therapeutic procedures in the neck region. *Acta Med Croatica* 2009;63 Suppl 3:21-7.
- Cesareo R, Palermo A, Pasqualini V, Cianni R, Gaspa G, Manfrini S, *et al.* Radiofrequency ablation for the management of thyroid nodules: A critical appraisal of the literature. *Clin Endocrinol (Oxf)* 2017;87:639-48.
- Papini E, Guglielmi R, Pacella CM. Laser, radiofrequency, and ethanol ablation for the management of thyroid nodules. *Curr Opin Endocrinol Diabetes Obes* 2016;23:400-6.
- Bandeira-Echtler E, Bergerhoff K, Richter B. Levothyroxine or minimally invasive therapies for benign thyroid nodules. *Cochrane Database Syst Rev* 2014;(6):CD004098.
- Haugen BR, Alexander EK, Bible KC, Doherty GM, Mandel SJ, Nikiforov YE, *et al.* 2015 American thyroid association management guidelines for adult patients with thyroid nodules and differentiated thyroid cancer: The American thyroid association guidelines task force on thyroid nodules and differentiated thyroid cancer. *Thyroid* 2016;26:1-33.
- Íñiguez-Ariza NM, Lee RA, Singh-Ospina NM, Stan MN, Castro MR. Ethanol ablation for the treatment of cystic and predominantly cystic thyroid nodules. *Mayo Clin Proc* 2018;93:1009-17.
- Negro R, Colosimo E, Greco G. Outcome, pain perception, and health-related quality of life in patients submitted to percutaneous ethanol injection for simple thyroid cysts. *J Thyroid Res* 2017;2017:9536479.
- Ozderya A, Aydin K, Gokkaya N, Temizkan S. Percutaneous ethanol injection for benign cystic and mixed thyroid nodules. *Endocr Pract* 2018;24:548-55.
- Fukumoto K, Kojima T, Tomonari H, Kontani K, Murai S, Tsujimoto F. Ethanol injection sclerotherapy for Baker's cyst, thyroglossal duct cyst, and branchial cleft cyst. *Ann Plast Surg* 1994;33:615-9.
- Kim SM, Baek JH, Kim YS, Sung JY, Lim HK, Choi H, *et al.* Efficacy and safety of ethanol ablation for thyroglossal duct cysts. *AJNR Am J Neuroradiol* 2011;32:306-9.
- Lee DK, Seo JW, Park HS, Kang MK, Jang AL, Lee JH, *et al.* Efficacy of ethanol ablation for thyroglossal duct cyst. *Ann Otol Rhinol Laryngol* 2015;124:62-7.
- Ha EJ, Baek SM, Baek JH, Shin SY, Han M, Kim CH. Efficacy and safety of ethanol ablation for branchial cleft cysts. *AJNR Am J Neuroradiol* 2017;38:2351-6.
- Wiegand S, Eivazi B, Zimmermann AP, Sesterhenn AM, Werner JA. Sclerotherapy of lymphangiomas of the head and neck. *Head Neck* 2011;33:1649-55.
- Nguyen MT, Orloff LA. Successful ablation of plunging ranula by ultrasound-guided percutaneous ethanol injection. *Laryngoscope* 2017;127:2239-41.
- Cheng PC, Chang CM, Huang CC, Lo WC, Huang TW, Cheng PW, *et al.* The diagnostic performance of ultrasonography and computerized tomography in differentiating superficial from deep lobe parotid tumours. *Clin Otolaryngol* 2019;44:286-92.
- Bennedbaek FN, Hegedüs L. Percutaneous ethanol injection therapy in benign solitary solid cold thyroid nodules: A randomized trial comparing one injection with three injections. *Thyroid* 1999;9:225-33.
- Bennedbaek FN, Nielsen LK, Hegedüs L. Effect of percutaneous ethanol injection therapy versus suppressive doses of L-thyroxine on benign solitary solid cold thyroid nodules: A randomized trial. *J Clin Endocrinol Metab* 1998;83:830-5.
- Mauz PS, Maassen MM, Braun B, Brosch S. How safe is percutaneous ethanol injection for treatment of thyroid nodule? Report of a case of severe toxic necrosis of the larynx and adjacent skin. *Acta Otolaryngol* 2004;124:1226-30.